DENTAVANTGART

labline

VOLUME IV ISSUE 02 SUMMER 2014



INTERVIEW

PERFECTER OF THE GOOD: KURT ZUBLER

DT. **ALEJANDRA SEQUEIRA** & DR. **JORDI MANAUTA**

COLOUR DROPS PROGRESSIVE WAX-UP IN COLORS

DR. **IVAN C. MOLINA** & TPD. **ELADIO GONZALEZ** & DR. **PASCAL MAGNE**

ULTRACONSERVATIVE ESTHETIC REHABILITATION USING VENEERS

DR. **JAVIER VASQUEZ**

A DIFFERENT PERSPECTIVE IN OCCLUSION

THE 3-STEP TECHNIQUE FOR THE IMMEDIATE IMPLANT PLACEMENT:

THE CLINICIAN-TECHNICIAN COLLABORATION TO ACHIEVE EXCELLENCE

CLINICIAN: Ramón Gómez Meda
TECHNICIAN: Santiago Dalmau

Esthetic appearance is of great significance for most people nowadays. A beautiful smile plays a key role in the appeal of the face and the ability of the individual to express emotions.

When a decayed tooth has to be treated and that tooth is located in the smile, it is of primordial importance the way we provisionalize the lost tooth. Immediate implant placement plus immediate provisionalization has the advantage of reducing the morbidity for the patient as well as the number of appointments. But not only that, immediate implant placement has the biological advantage of avoiding raising a flap preserving the integrity of the vascularization and as a consequence improving the preservation of the socket. Immediate provisionalization also has the advantage of preserving the shape of the soft tissues as well as the well-being and self-steem of the patient who is able to continue with his normal social activity.

But there are disadvantages, of course. We have learned how to minimize the risk of losing the implant by using new implant designs and under-drilling the implant site. So, with time, we found the disadvantage of having to reshape the temporary restoration in order to get an ideal emergence profile. After that, the emergence profile had to be replicated and sent to the laboratory to fabricate the final restoration.

We have solved this problem by means of:

Firstly: Grafting a connective tissue graft between the bucal cortical plate and the the gingiva, so we compensate the collapse of the socket that happens after taking out a tooth due to the remodeling of the bundle bone.

Secondly: Using the crown of the textrated tooth to achieve an optimal emergence shape keeping the original shape and color of the tooth

Thirdly: Replicating the emergence profile at the same time as placing the temporary restoration. No reshaping of the temporary is usually necessary due to the preservation of the socket by means of grafting a CTG.

In this way, we are able to finish the whole case in only three appointments in most cases. With this technique the patients keeps their well-being and self-esteem . They end up very satisfied with the final treatment and the speed with which it was achieved.

In this article, we show a summary of the 3-Steps technique in immediate implant plus immediate provisionalization.



[1] Pre-operative situation: The patient came to our office with a vertical fracture in her first premolar, reporting pain during biting and chewing.

[2] Preoperative situation showing the lateral view which involved the broken premolar.

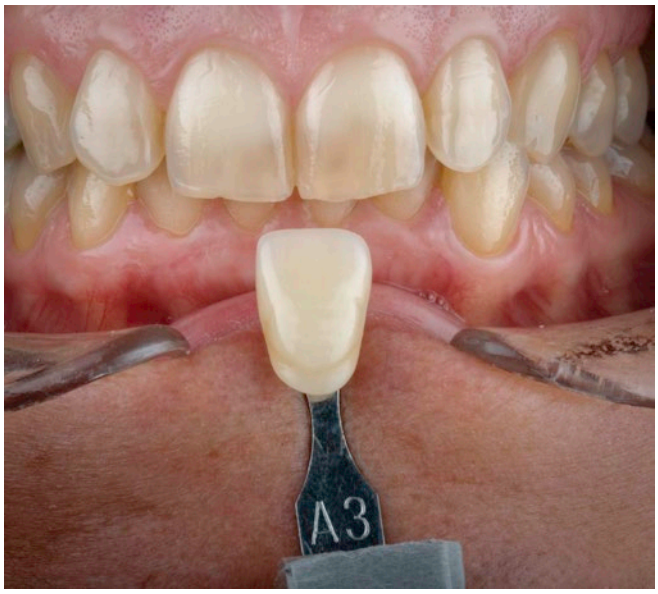

[3] A color registration was taken because the patient desire was to bleach the dentition at the end of the treatment.

[4] Initial intraoral situation showing the vertical fracture in a tooth endodontically treated many years ago.

FIRST TREATMENT STEP

[5] The crown of the tooth will be used to fabricate the temporary restoration after hollowing it.

[6] A 4.6 mm implant with a platform–switching design and a laser-lock technology was placed (Bihorizons Tapered Implant Plus).

[7] The temporary abutment is tried along with the hollowed crown of the tooth.

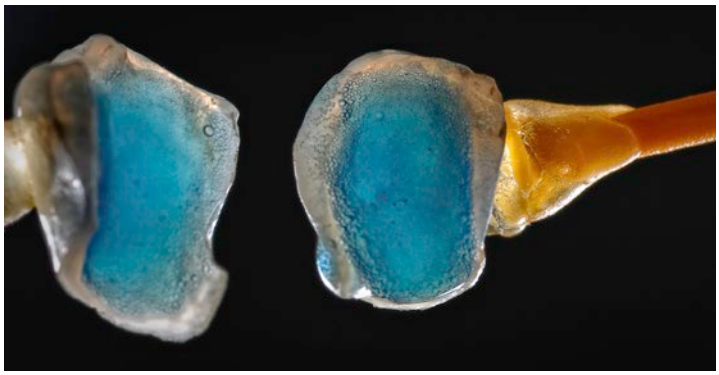

[8] The internal part of the crown is etched and rinsed.

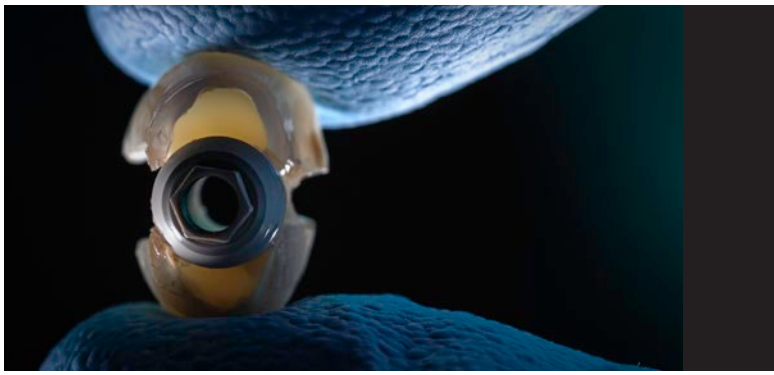

[9] The temporary abutment is bonded into the mouth to both parts of the crown using a composite.

[10] After cleaning the crown, this is finished adding more composite. A good polishing and shining of the surface of the crown is advisable.

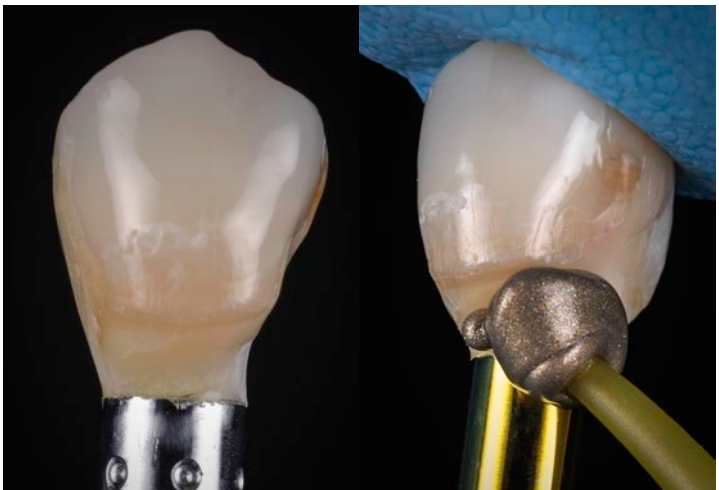

[11] The emergence profile is replicated with the use of an A-silicone. This step will allow us to individualize an impression coping for the second appointment.

[12] After that, a tunnel is performed between the gingiva and the bucal cortical plate to allocate the connective tissue graft.

[13] The connective tissue is grafted from the tuberosity and introduced in the socket.

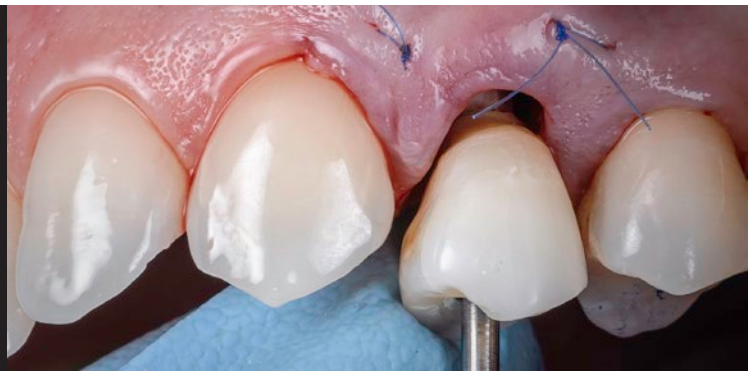

[14] Then, the temporary restoration is screwed in and the oclussion checked.

[15] Appearance after the healing period.

SECOND TREATMENT STEP

[16] During the second treatment appointment we check the emergence profile of the temporary crown, and if this is alright, no reshaping of the temporary will be necessary.

[17] The profile of the gingiva is preserved in the vertical and horizontal dimension. The individualized impression coping fits exactly in the shape of the gingival.

In this way transfer all the information of the soft tissues and the position of the implant and we obtain a master model that reproduces faithfully the emergency perfilde.

[18] A CAD_CAM zirconia abutment is customized but a metallic interface is standardized and utilized in contact with the implant.

The zirconia part of the abutment is computer assisted designed (CAD) respecting the emergence profile obtained with the provisionalization, taking advantage of the qualities of the material in contact with the soft tissue.

The zirconia abutment is glued to the metallic interface

[19] The zirconium coping is designed compensating the thicknesses of the coating material in order to minimize any possible chipping

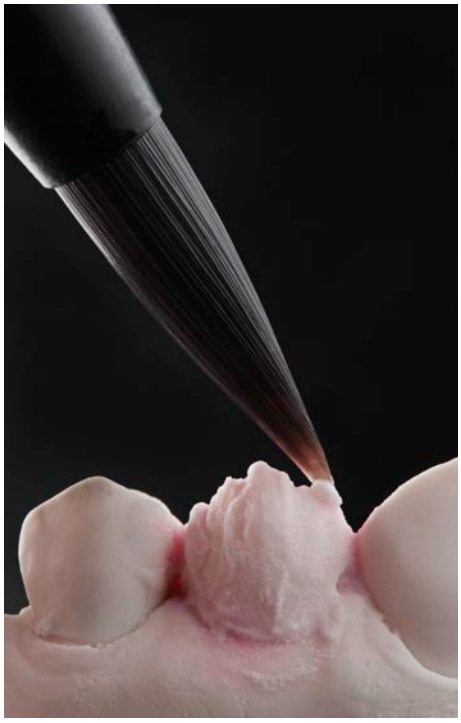

[20] Steps of the ceramic workflow.

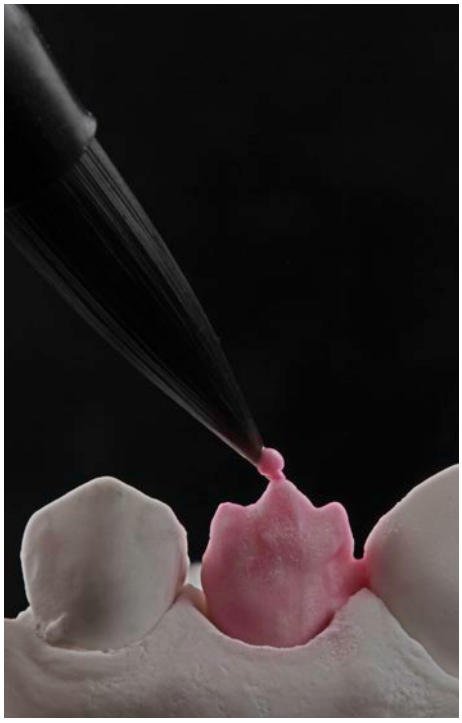

[21] In this case VITA VM9 ceramic is used with a layering stratification technique. The coating begins with a saturated dentin to control the overall value of the restoration core.

The build up continues with transparent dentin and modifiers.

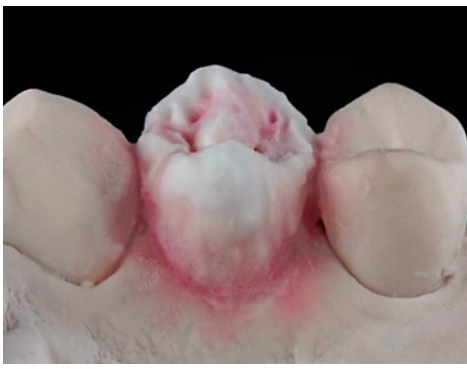

[22] Palatal view of the anatomy of the crown before baking.

[23] The completion of the layering with opalescent, translucent and enamel. The macromorphology is defined by the occlusion and anatomical characteristics of the patient.

[24] Colour matching. Comparison between the registered color and the final crown.

[25] The anatomy is completed by adding details before the second baking.

[26] Different views of the final anatomy of the crown before the second baking.

THIRD TREATMENT STEP

[27] No try-in was executed before the third appointment. This is the moment we placed the zirconia abutment for the first time.

[28] And the final restoration.

[29] A harmonic result between the pink and white portion of the smile was achieved.

[30] After checking the occlusion.

[31] The resulting smile preserving a balance between the pink and white portion of the restoration, achieved only with one initial diagnostic appointment and a three-step treatment approach.

[32] One more bleaching session was applied after placing the crown to increase the value of the teeth.

[34] The gingival display of the smile is quite relevant in many young patients, being quite important to get a nice emergence profile and pink esthetic result.

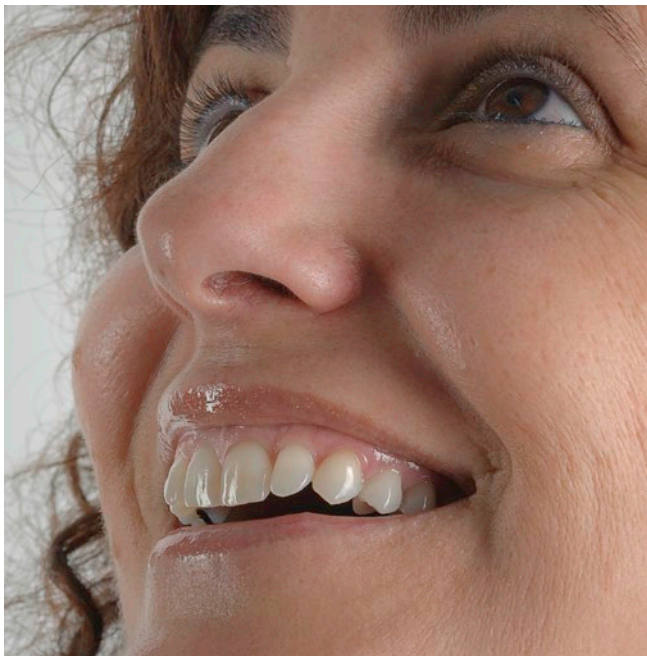

[33] Different pictures showing the final result achieved with only three appointments.



[35] Frontal photographic evaluation of the smile and face of the patient is not enough in order to assess a gingival smile. Video recording or photo shooting in different angles are also necessary.

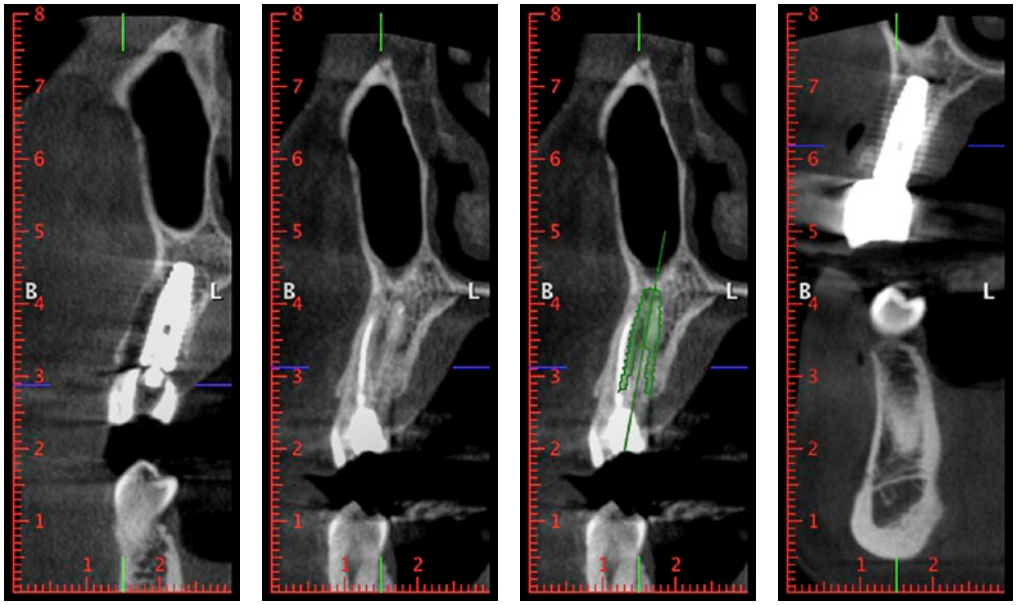

[36] Tomographic sequence of the treatment: before, planning, after placing the implant and the temporary restoration and the follow-up six months later.

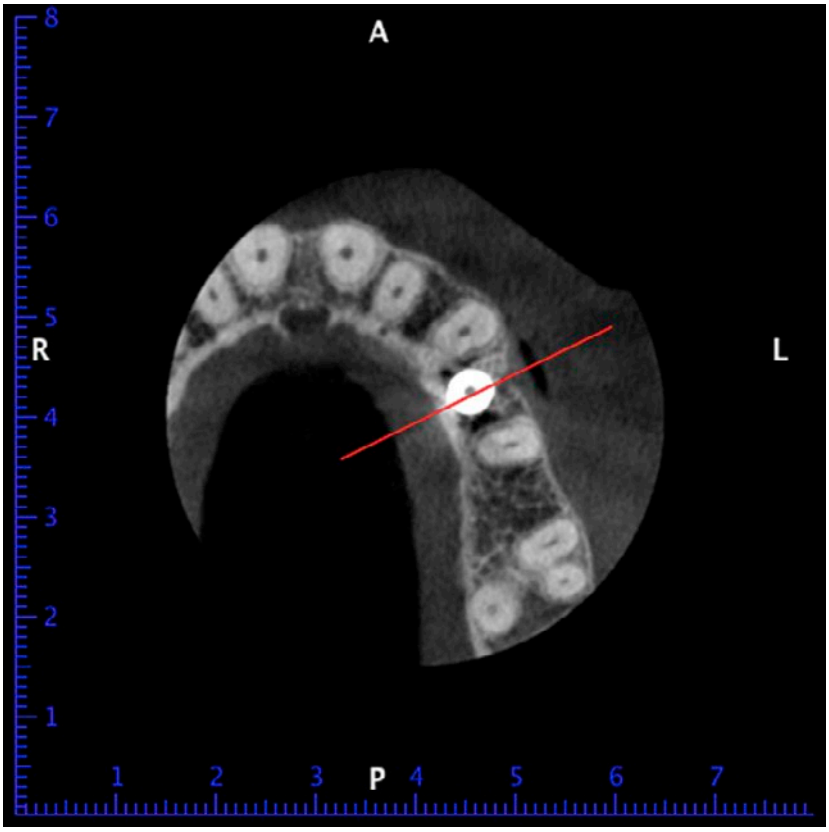

[37] Cortical bone plate is preserved 1 year later.

[38] Radiographic sequence: initial situation, with the provisional, and with the final restoration.



[39] Final result, showing a broad smile and the satisfaction of the patient with the result.

RAMÓN GÓMEZ MEDA,

DDS.

DENTIST,
SPAIN

Dr. Ramón Gómez Meda obtained his Degree in Dentistry from the University of Santiago de Compostela in 1996 with the best marks. As a result, he obtained the Thesis Award of the Autonomous Community of Galicia for Academic Excellence and a Grant from the College of Dentists of Cordoba to the best academic record among the Spanish dental schools. He has been distinguished with several more grants and awards through his professional career. He decided to study every field in dentistry against the advice of many of his professors: a Master of Occlusion and Temporo-mandibular Dysfunction (Valencia, 98) and a postgraduate training in Orthodontics with Prof.. David Suarez Quintanilla in the University of Santiago de Compostela (98-99). He graduated in Periodontics and Implantology (Madrid 99-00) and completed his studies with clinical stays in colleges, hospitals and clinics in Europe and America. Ex-partner of the departments of Restorative Dentistry, Endodontics and Surgery at the University of Santiago de Compostela. He maintains a private practice in Ponferrada (León) since 2001. He is a member of several scientific societies: AEDE (Spanish Association for Endodontics), SEPA (Spanish Association for Periodontology and Osseointegration), SEPES (Spanish Association for Dental Prosthestics), SEI (Spanish Implants Association), being a frequent speaker for SEPES in the field of multidisciplinary rehabilitation. He has published more than 30 articles about hard and soft tissue grafting techniques as well as multidisciplinary treatments. He is a clinical investigator of new implant surfaces and biomaterials for Zimmer Dental. Lately, he has been lecturing very intensively nationally and internationally on Endodontics, Periodontics, Implantology and Aesthetic Multidisciplinary Treatments for universities, study groups, professional societies, websites (Dental-XP,Dentared,Mozo-Grau...) and companies (Biohorizons, Dentsply Implants, Zimmer, Geistlich Biomaterials,...). At present, he is a lecturer for the Continuing Education Committee of the General Dental Spanish Council since 2011.

SANTIAGO DALMAU,

CDT.

DENTAL TECHNICIAN,
SPAIN

- Dental Technician since 1988 in the Dental Tecknic Gnathology German Institute
- Continued training with many national and international courses in France Germany, Italy, the Netherlands, Portugal, Belgium and so on ... specializing in fixed prosthodontics, aesthetics and implantology
- Technical Manager of different laboratories for over 25 years
- Lecturer in many national and international conferences and symposiums
- Collaborations in books: "Oral Implant Prosthetic Rehabilitation" and "Immediate loading in implant dentistry" written by Dr Jimenez López and translated into more than five languages
- Articles published in national and international scope
- Associate professor of occlusion in UDIMA prosthesis, UEM (European University of Madrid), and the Complutense University of Madrid .
- Professor of the Master of Implantology at the European University since 2004
- Currently, director of the Dalmau Dental Laboratory in Madrid since 2006

PHOTO: DR. ÁRPÁD MENTES