Autotransplantation of Mandibular Third Molar with Buccal Cortical Plate to Replace Vertically Fractured Mandibular Second Molar: A Novel Technique

Juan Zufía, DDS, MSc, Francesc Abella, DDS, PhD,† Ivan Trebol, DDS, MSc,* and Ramón Gómez-Meda, DDS, MSc‡*

Abstract

Tooth replacement often leads to inadequate vertical volume in the recipient site bone when a tooth has been extracted because of a vertical root fracture (VRF). This case report presents the autotransplantation of a mandibular third molar (tooth #32) with the attached buccal cortical plate to replace a mandibular second molar (tooth #31) diagnosed with a VRF. After extraction of tooth #31, the recipient socket was prepared based on the size measured in advance with cone-beam computed tomographic imaging. The precise and calculated osteotomy of the cortical bone of tooth #32 allowed for the exact placement of the donor tooth in the position of tooth #31. The total extraoral time was only 25 minutes. The block was fixed to the recipient socket with an osteosynthesis screw and splinted with a double resin wire for 8 weeks. At the 6-month follow-up, the screw was removed, and the stability of the tooth and the regeneration obtained throughout the vestibular area were confirmed. At the 2-year follow-up, the transplanted tooth was asymptomatic and maintained a normal bone level. Advantages of autotransplantation over dental implants include maintenance of proprioception, possible orthodontic movements, and a relatively low cost. This case report demonstrates that an autotransplantation of a third molar attached to its buccal cortical plate is a viable option to replace teeth with a VRF. *(J Endod 2017;■:1–5)*

Key Words

Autotransplantation, buccal cortical plate, complete root formation, periodontal ligament, vertical root fracture

Significance

Autotransplantation can provide an alternative to dental implants in patients with inadequate bone support because of a vertical root fracture.

Autotransplantation is the transplantation of embedded or erupted teeth in the same individual from one site to another into extraction sites or surgically prepared sockets (1). Indications for tooth autotransplantation include impacted or ectopic teeth, premature and/or traumatic tooth loss, loss of teeth because of tumors or iatrogenesis, congenitally missing teeth, replacement of teeth with a poor prognosis, and/or developmental anomalies when a suitable donor tooth is available (2, 3).

Successful tooth transplantation depends on proper case and patient selection (4, 5). It depends above all on the vitality of the remaining periodontal ligament (PDL) cells in the donor root, the shape and the site of the recipient socket, and the vascularity of the recipient bed (6, 7). Since the 1990s, many studies on periodontal tissues, periodontal membrane, and dental root resorption have shown that the transplant success rate is rapidly increasing, which is giving rise to new clinical interest (3, 8, 9). It should be noted that most studies have focused on the autotransplantation of teeth with incomplete root formation (10–12), which restricts the applications of tooth autotransplantation to patients in their early 20s and younger. However, previous research has determined no substantial difference in the autotransplantation success rate between mature and immature teeth (3, 8, 9). Tsukiboshi (3) reported a 90% survival rate and an 82% success rate for 250 cases observed over 6 years; these results are similar to those obtained by Lundberg and Isaksson (8) and Mejàre et al (9). Therefore, teeth with complete root formation should be considered for use as donor teeth.

The most frequently reported complications in teeth autotransplantation include inflammatory root resorption, replacement root resorption or ankylosis (2, 3, 8, 13), pulp necrosis (9, 14), lack of periodontal healing (5, 9), and reduction of final root length (12, 15, 16). Hence, for successful tooth autotransplantation, it is essential to preserve as many viable cells as possible in the donor tooth root and promote the formation of new PDL in the recipient site. Efforts to maintain viable cells in the donor tooth facilitate the preservation of cervical root cells, which can be easily damaged during tooth extraction and allow for bone healing around the donor tooth (17).

Tooth replacement often leads to an inadequate vertical volume in the recipient site bone when a significant period has passed since tooth extraction or extraction

From the *Private Practice, Madrid, Spain; †Department of Restorative Dentistry and Endodontics, Universitat Internacional de Catalunya, Sant Cugat del Vallès, Barcelona, Spain; and ‡Private Practice, Ponferrada, Spain.

Address requests for reprints to Dr Francesc Abella, Dentistry Faculty, Universitat Internacional de Catalunya, C/Josep Trueta s/n, Sant Cugat del Vallès, 08195, Barcelona, Spain. E-mail address: franabella@uic.es

0099-2399/$ - see front matter

Copyright © 2017 American Association of Endodontists.

http://dx.doi.org/10.1016/j.joen.2017.03.023

resulting from a periodontal problem or a vertical root fracture (VRF). The aim of this report was to present an atraumatic and precise surgical technique guided by cone-beam computed tomographic (CBCT) imaging for osteotomy preparation of donor sites. The case report focuses on the autotransplantation of a mandibular third molar still attached to its buccal cortical plate to replace a mandibular second molar with a VRF.

Case Report

In May 2015, a 35-year-old woman was referred for evaluation of her mandibular right second molar (tooth #31). The medical history was noncontributory. The patient's chief complaint was of a purulent discharge from tooth #31 and pain on biting over the preceding 4 months. Clinical examination revealed that it had a restoration of resin composite and was sensitive to vertical percussion (Fig. 1*A*). At the time of the exploration, a draining sinus tract was not evident, and tooth mobility was within physiologic limits. Periodontal probing revealed local pocketing almost to the apex on the mesiobuccal and distobuccal region of tooth #31 (Fig. 1*B*).

Radiographic examination revealed an extensive furcation, crestal, and periapical bone resorption of tooth #31 (Fig. 1*C*). These clinical, periodontal, and radiographic findings led us to suspect a VRF. During this appointment, an interdisciplinary treatment plan was formulated; the patient was informed that tooth #31 had a questionable long-term prognosis because of the possible VRF. A small-volume CBCT image was taken (Planmeca 3Ds; Planmeca Oy, Helsinki, Finland) to reveal the pattern of bone destruction, the involvement of the buccal cortical plate, and a possible line of fracture. A complete loss of the buccal cortical plate was observed in the axial, sagittal, and coronal sections (Fig. 1*D–F*). The axial images showed an extensive bone resorption in both the buccal and lingual surface (Fig. 1*D*). However, no radiolucent line was detected compatible with a VRF.

Clinically and radiographically, the mandibular third molar (tooth #32) was completely erupted and positioned within the dental arch and without an antagonist, making it possible for tooth autotransplantation. The treatment plan included extraction of fractured tooth #31 and autotransplantation of tooth #32 with the buccal cortical plate in order to vertically regenerate the bone defect. Informed consent was obtained for the treatment.

Endodontic treatment of tooth #32 was completed preoperatively (48 hours before autotransplantation) to reduce the extraoral time. The volumetric size of the donor tooth was analyzed from CBCT images to calculate the suitability of the transplant as well as the buccal cortical size to be taken.

Surgical Procedure

After local anesthesia, a mucoperiosteal flap surrounding teeth #31 and #32 was raised. As we expected, a full dehiscence of the buccal plate was observed in tooth #31, and a fracture line was visible in the 2 exposed roots, confirming a definitive diagnosis of VRF (Fig. 2*A–C*). After extraction, the recipient socket was prepared with a surgical round bur with copious saline irrigation based on the size measured in advance on CBCT imaging. All the granulation tissue in the extraction socket defect was thoroughly cleaned (Fig. 2*D–F*). To reduce the injury to the PDL of the donor tooth and regenerate the bone defect in the recipient socket, tooth #32 was extracted carefully with the attached buccal cortical plate. A precise and calculated osteotomy of the cortical bone of tooth #32 was made (Fig. 3*A–D*). This allowed the exact placement of the donor tooth in the position of tooth #31 and completely replaced the recipient socket. The tooth was stored in physiologic saline–soaked gauze during the extraoral procedure. The block was fixed to the recipient socket with an osteosynthesis screw (Fig. 3*E*). Then, the transplanted tooth was splinted with a double resin wire splint (buccal

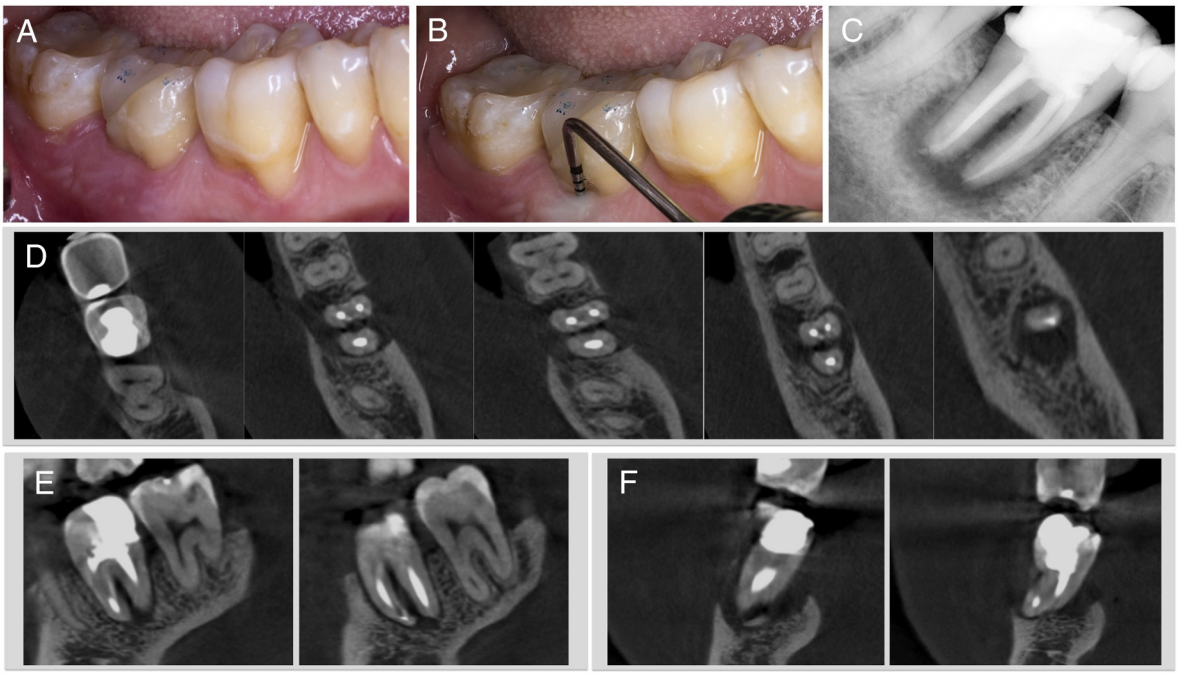

Figure 1. (*A*) A 35-year-old woman was referred for evaluation of her mandibular right second molar (tooth #31). (*B*) Periodontal probing revealed local pocketing almost to the apex on the mesiobuccal and distobuccal region of tooth #31. (*C*) Tooth #31 with endodontic treatment and clinical signs of VRF. Note the extensive furcation, crestal, and periapical bone resorption. (*D*) The reconstructed axial CBCT (Planmeca 3Ds) images showed an extensive bone resorption in the buccal and lingual surface. (*E*) The sagittal view. (*F*) Coronal CBCT images revealed a complete loss of the buccal cortical plate of tooth #31. The fracture was not visible on either imaging modality.

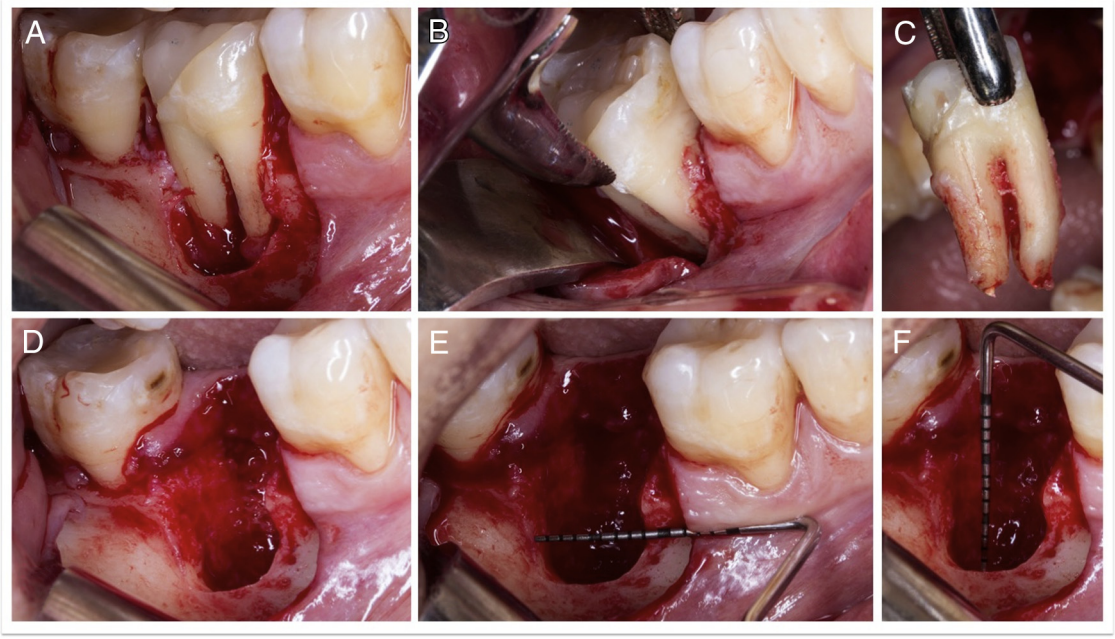

Figure 2. (*A*) The suspected VRF was only confirmed during the surgical flap. (*B*) Extraction of tooth #31. (*C*) A fracture line was visible in the mesial and distal root. (*D*) All the granulation tissue in the socket defect was cleaned. (*E* and *F*) The recipient socket preparation was guided according to the preoperative CBCT image.

and lingual) for 8 weeks (Fig. 3*F* and *G*). The splint was passive and semirigid, maintaining physiologic tooth mobility. It was not necessary to correct any occlusal interference because the clinical crown of tooth #32 was shorter in length than the crown of tooth #31.

The patient was examined every month during the first year and then at 2 years after surgery. At the 6-month follow-up, the screw was removed, and the stability of the tooth and the regeneration obtained throughout the vestibular area were verified (Fig. 4*A*). After 2 months, a lithium disilicate overlay with a circumferential adhesive ferrule effect was performed (Fig. 4*B–D*). At the 2-year follow-up, the transplanted tooth was asymptomatic and maintained a normal bone level (Fig. 4*E*). The radiographs revealed no replacement or inflammatory root resorption of the transplant. No bone furcation defect was observed, indicating that there was no vertical resorption of the bone fragment (Fig. 4*F*).

Discussion

A VRF in endodontically treated teeth is 1 of the most frustrating complications of root canal treatment, which results in tooth or root extraction (18–20). VRF is a longitudinally oriented fracture of the

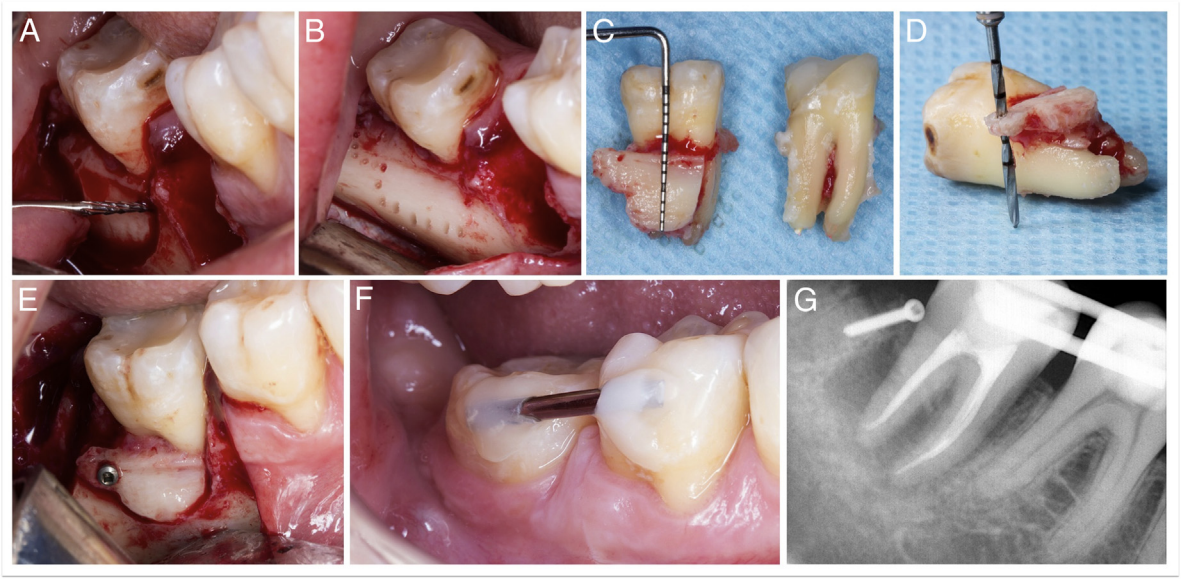

Figure 3. (*A* and *B*) A precise and calculated osteotomy guided by the CBCT image of the cortical bone of tooth #32. (*C*) A comparison of size between teeth #31 and #32. (*D* and *E*) The block was fixed to the recipient socket with an osteosynthesis screw. (*F*) A double resin wire splint. (*G*) A periapical radiograph confirming the correct position of the tooth after replantation and splinting. The transplanted tooth was positioned below the occlusal plane.

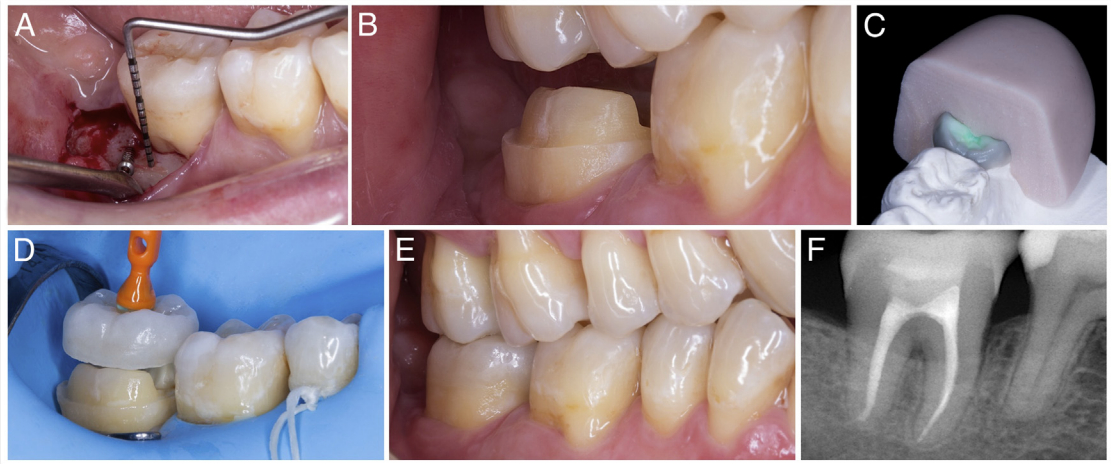

Figure 4. (*A*) Removal of the osteosynthesis screw. Note the bone regeneration obtained throughout the vestibular area. (*B*) Details of the overlay preparation of the transplanted tooth. (*C*) The laboratory painted lithium disilicate wax-up. (*D*) Try-in and small occlusal check of the restoration without rubber dam isolation. (*E*) Lithium disilicate painted overlay after the adhesive cementation. (*F*) The 2-year radiographic follow-up showing normal bone contour around the tooth.

root that originates from its apical end and propagates coronally and is defined as 1 of the crack types (21). In many cases of tooth replacement, an inadequate vertical volume in the recipient site bone is observed when a significant period has passed after tooth extraction or when a tooth has been extracted because of a periodontal problem or a VRF. When aVRF is diagnosed, the inflammation in the supporting tissues leads to periodontal breakdown followed by the development of a deep osseous defect and resorption of the bone facing the root fracture (19). Tsesis et al (22) concluded that a definitive diagnosis of VRF can only be reached through a flap surgical procedure, after a tooth extraction, or radiographically when there is a clearly discernable separation of fractured root segments. In the presented case, a full dehiscence of the buccal plate with bone resorption extending into the interproximal area was observed after raising a mucoperiosteal flap.

Advantages of autotransplantation over dental implants include maintenance of proprioception, possible orthodontic movements, relatively low cost, and pulpal regeneration with immature teeth (3, 23). According to some studies (24–26), bone regeneration can be induced at the recipient site after transplantation when the PDL cells of the donor tooth root are preserved. Theoretically, both horizontal and vertical bone growth is possible (27), but few cases have shown vertical growth in the case of mature third molar autotransplantation (17, 28). Zhang et al (29) reported that the regenerative potential of PDL cells is reduced with aging, which might interfere with the normal adaptation of the donor tooth on the recipient site. Hence, we preferred to use an atraumatic surgical technique and perform an autotransplantation of the mandibular third molar (tooth # 32) with the attached buccal cortical plate.

The most important factor for the success of autogenous tooth transplantation is the vitality of the PDL attached to the transplanted tooth (27). The PDL is sensitive to pH and osmotic potential, and its viability is reduced if the extraoral dry time is long (30). In this case, the tooth was held gently at both the crown and root with gauze soaked in physiologic saline. An extraoral time less than 20 minutes is associated with a positive effect on tooth survival (30), which is consistent with the results of studies on intentional replantation (31, 32). In this case report, the total extraoral time was only 25 minutes, allowing us to avoid the application of any solution, such as tetracycline, citric acid, EDTA, or enamel matrix derivative, to the root surface to enhance PDL fiber attachment or prevent ankylosis (33, 34). In this regard, the previous measurements we performed using CBCT imaging were essential to minimize the extraoral time. Another valid option is the use of computer-aided rapid prototyping models (17, 23, 35).

A recent systematic review provided the first evidence of outcomes of autotransplanted teeth with complete root formation (36). Rates of failure, infection-related root resorption, and ankylosis were occasionally observed in autotransplanted teeth with complete root formation. Teeth with fully developed roots are usually endodontically treated before transplantation because revascularization and pulpal healing are less likely to occur (3). In this way, inflammatory procedures that could endanger their prognosis are usually prevented (6, 9).

Conclusions

Autotransplantation can provide an alternative to the dental implant in some patients in whom dental implants become difficult because of inadequate bone support and in patients in growing stages. On the basis of this case, an autotransplantation of a third molar attached to its buccal cortical plate is a viable option to replace teeth with VRF.

Acknowledgments

The authors deny any conflicts of interest related to this study.

References

1. Natiella JR, Armitage JE, Greene GW. The replantation and transplantation of teeth. A review. Oral Surg Oral Med Oral Pathol 1970;29:397–419.
2. Tsukiboshi M, Andreasen J, Asai Y. *Autotransplantation of Teeth*. Chicago, IL: Quintessence; 2001. 10–14, 97, 152–167.
3. Tsukiboshi M. Autotransplantation of teeth: requirements for predictable success. Dent Traumatol 2002;18:157–80.
4. Northway WM, Konigsberg S. Autogenic tooth transplantation. The "state of the art". Am J Orthod 1980;77:146–62.
5. Andreasen JO, Paulsen HU, Yu Z, Schwartz O. A long-term study of 370 autotransplanted premolars. Part III. Periodontal healing subsequent to transplantation. Eur J Orthod 1990;12:25–37.
6. Nethander G, Skoglund A, Kahnberg KE. Experimental autogenous tooth transplantation in the dog: a comparison between one- and two-stage surgical techniques. Acta Odontol Scand 2003;61:223–9.
7. Katayama A, Ota M, Sugito H, et al. Effect of proliferating tissue on transplanted teeth in dogs. Oral Surg Oral Med Oral Pathol Oral Radiol Endod 2006;101:e110–8.
8. Lundberg T, Isaksson S. A clinical follow-up study of 278 autotransplanted teeth. Br J Oral Maxillofac Surg 1996;34:181–5.

9. Mejàre B, Wannfors K, Jansson L. A prospective study on transplantation of third molars with complete root formation. Oral Surg Oral Med Oral Pathol Oral Radiol Endod 2004;97:231–8.
10. Nagori SA, Jose A, Bhutia O, Roychoudhury A. Evaluating success of autotransplantation of embedded/impacted third molars harvested using piezosurgery: a pilot study. Acta Odontol Scand 2014;72:846–51.
11. Kallu R, Vinckier F, Politis C, et al. Tooth transplantations: a descriptive retrospective study. Int J Oral Maxillofac Surg 2005;34:745–55.
12. Bauss O, Zonios I, Rahman A. Root development of immature third molars transplanted to surgically created sockets. J Oral Maxillofac Surg 2008;66:1200–11.
13. Akkocaoglu M, Kasaboglu O. Success rate of autotransplanted teeth without stabilisation by splints: a long- term clinical and radiological follow-up. Br J Oral Maxillofac Surg 2005;43:31–5.
14. Andreasen JO, Paulsen HU, Yu Z, et al. A long-term study of 370 autotransplanted premolars. Part II. Tooth survival and pulp healing subsequent to transplantation. Eur J Orthod 1990;12:14–24.
15. Kristerson L. Autotransplantation of human premolars. A clinical and radiographic study of 100 teeth. Int J Oral Surg 1985;14:200–13.
16. Bauss O, Schwestka-Polly R, Hoy L, Kiliaridis S. Influence of orthodontic movement on root length of autotransplanted imma- ture third molars. Eur J Oral Sci 2004; 112:12–8.
17. Kim S, Lee SJ, Shin Y, Kim E. Vertical bone growth after autotransplantation of mature third molars: 2 case reports with long-term follow-up. J Endod 2015;41: 1371–4.
18. Walton RE, Michelich RJ, Smith GN. The histopathogenesis of vertical root fractures. J Endod 1984;10:48–56.
19. Tamse A. Vertical root fractures in endodontically treated teeth: diagnostic signs and clinical management. Endod Topics 2006;13:84–94.
20. Tamse A, Fuss Z, Lustig J, Kaplavi J. An evaluation of endodontically treated vertically fractured teeth. J Endod 1999;25:506–8.
21. Colleagues for excellence. *Cracking the Cracked Tooth Code: Detection and Treatment of Various Longitudinal Tooth Fractures*. Chicago, IL: American Association of Endodontics; 2008.
22. Tsesis I, Rosen E, Tamse A, et al. Diagnosis of vertical root fractures in endodontically treated teeth based on clinical and radiographic indices: a systematic review. J Endod 2010;36:1455–8.
23. Jang JH, Lee SJ, Kim E. Autotransplantation of immature third molars using a computer-aided rapid prototyping model: a report of 4 cases. J Endod 2013;39:1461–6.
24. Bright R, Hynes K, Gronthos S, Bartold PM. Periodontal ligament-derived cells for periodontal regeneration in animal models: a systematic review. J Periodontal Res 2015;50:160–72.
25. Seo BM, Miura M, Gronthos S, et al. Investigation of multipotent postnatal stem cells from human periodontal ligament. Lancet 2004;364:149–55.
26. Liu Y, Zheng Y, Ding G, et al. Periodontal ligament stem cell-mediated treatment for periodontitis in miniature swine. Stem Cells 2008;26:1065–73.
27. Andreasen JO. Interrelation between alveolar bone and periodontal ligament repair after replantation of mature permanent incisors in monkeys. J Periodontal Res 1981;16:228–35.
28. Plakwicz P, Czochrowska EM, Milczarek A, Zadurska M. Vertical bone growth following third molar to replace a retained mandibular permanent molar: a case report. Int J Periodontics Restorative Dent 2014;34:667–71.
29. Zhang J, An Y, Gao LN, et al. The effect of aging on the pluripotential capacity and regenerative potential of human periodontal ligament stem cells. Biomaterials 2012; 33:6974–86.
30. Jang Y, Choi Y, Lee SJ, et al. Prognostic factors for clinical outcomes in autotransplantation of teeth with complete root formation: survival analysis for up to 12 years. J Endod 2016;42:198–205.
31. Cho SY, Lee Y, Shin SJ, et al. Retention and healing outcomes after intentional replantation. J Endod 2016;42:909–15.
32. Jang Y, Lee SJ, Yoon TC, et al. Survival rate of teeth with a C-shaped canal after intentional replantation: a study of 41 cases for up to 11 years. J Endod 2016;42:1320–5.
33. Zucchelli G, Mele M, Checchi L. The papilla amplification flap for the treatment of a localized periodontal defect associated with a palatal groove. J Periodontol 2006;77: 1788–96.
34. Zaman KU, Sugaya T, Hongo O, Kato H. A study of attached and oriented human periodontal ligament cells to periodontally diseased cementum and dentin after demineralizing with neutral and low pH etching solution. J Periodontol 2000;71:1094–9.
35. Bae JH, Choi YH, Cho BH, et al. Autotransplantation of teeth with complete root formation: a case series. J Endod 2010;36:1422–6.
36. Chung WC, Tu YK, Lin YH, Lu HK. Outcomes of autotransplanted teeth with complete root formation: a systematic review and meta-analysis. J Clin Periodontol 2014;41: 412–23.